



PATIENT

Belle Rusin

SPECIES

Canine

BREED

Pitbull Mix

SEX

Female Spayed

PRESENTING CLINICAL SIGNS

History: History of coughing after going up stairs. Started in mid Jan, about the same frequency not getting worse. Cough started a little before her splenectomy surgery.

RADIOGRAPHIC FINDINGS *NOTE: Images submitted for supplemental cardiac information only.
Normal cardiac silhouette. No obvious evidence of CHF.

ECHOCARDIOGRAM FINDINGS

2D, m-mode, color flow and doppler imaging is available. Normal mitral valve leaflets with no prolapse into the left atrial lumen. Trivial mitral regurgitation with no left atrial dilation. Normal LV diameter with borderline myocardial function. The tricuspid valve appears normal with trivial tricuspid regurgitation. Normal velocity. Normal right atrial and ventricular diameter and morphology indicating no overt evidence of pulmonary arterial hypertension. The pulmonic and aortic valves are normal in morphology and mobility. Normal pulmonic and aortic outflow velocities with laminar flow. No obvious aortic or pulmonic insufficiency. No pericardial or pleural effusion noted. No obvious cardiac masses.

CARDIAC CHART

AGE

9 years

WEIGHT

57lbs

INTERPRETED BY

Maggie Machen Lamy,
DVM, DACVIM
(Cardiology)

IMAGING PERFORMED BY

Amy Mayhew, LVT

HOSPITAL NAME

SVS Imaging MI

REFERRING VET

Family Pet Practice

INVOICE

23601

DATE

4/12/22

CANINE CARDIAC PARAMETERS	MR VMAX (m/s)	TR VMAX (m/s)	LA/AO (Boon method)	LA/AO (Heart Base; Swe)	FS (%)	EF (%)	EPSS (cm)
NORMAL PARAMETER	4.5-5.5	<2.7	1.3	<1.6	28-40	40-100	<0.6
PATIENT	NM	1.8	NM	1.3	26	51	NM
CANINE CARDIAC PARAMETERS	HR (BPM)	AV VMAX (m/s)	PV MAX (m/s)	BODY WEIGHT (kg)	LA 2D short axis Base view (cm)	LVIDd Avg; 2D and m-mode short axis (cm)	LVIDs Avg; 2D and m-mode short axis (cm)
NORMAL PARAMETER	50-100	0.7-1.7	0.7-1.6	BELOW	BELOW	BELOW	BELOW
PATIENT	NM	1.3	0.75	25.9	2.6	4.3	3.2
*Normal chamber parameters expressed as a mean value (SD)				3	1.27 (5.3)	2.46 (2.46)	1.36 (5.5)
BODY WEIGHT DEPENDENT PARAMETERS				5	1.40 (4.5)	2.74 (5.2)	1.60 (4.7)
<i>*Note: All measurements based upon multi-modal images and methods. An average value is reported.</i>				10	1.50 (3.8)	3.27 (3.5)	2.06 (3.1)
				15	1.83 (2.0)	3.71 (2.4)	2.43 (2.1)
				20	2.02 (1.9)	4.14 (2.2)	2.80 (2.0)
				25	2.18 (2.4)	4.48 (2.9)	3.10 (2.5)
				30	2.33 (3.3)	4.83 (3.9)	3.39 (3.4)
				35	2.48 (4.3)	5.17 (5.0)	3.69 (4.5)
				40	2.62 (5.2)	5.48 (6.1)	3.96 (5.4)
				50	2.88 (7.1)	6.07 (8.3)	4.46 (7.4)

INTERPRETATION OF THE FINDINGS & FURTHER RECOMMENDATIONS

Overtly normal cardiac dimensions and function, with no obvious dysfunction or dilation of the left heart. Trivial leaks are noted in the mitral and tricuspid valves and follow up is advised should a murmur be ausculted in the future. Additionally, the systolic function is borderline for this signalment, and monitoring is advised. Avoid non-traditional diets in this patient going forward. No additional issues are identified.

IMAGING PERFORMED BY

svsmobileimaging.com 309-737-3070

**PATIENT**

Belle Rusin

No cardiac medications are indicated at this time as the **cough appears non-cardiac in origin**. Continued work up for infectious/inflammatory respiratory causes is recommended. Options include Baytril or similar antibiotic, anti-inflammatory prednisone, aggressive hydrocodone, etc. If refractory, may consider TTW/BAL for further information.

SPECIES

Canine

Monitor for development of a heart murmur, cough, labored breathing, exercise intolerance or collapse episodes.

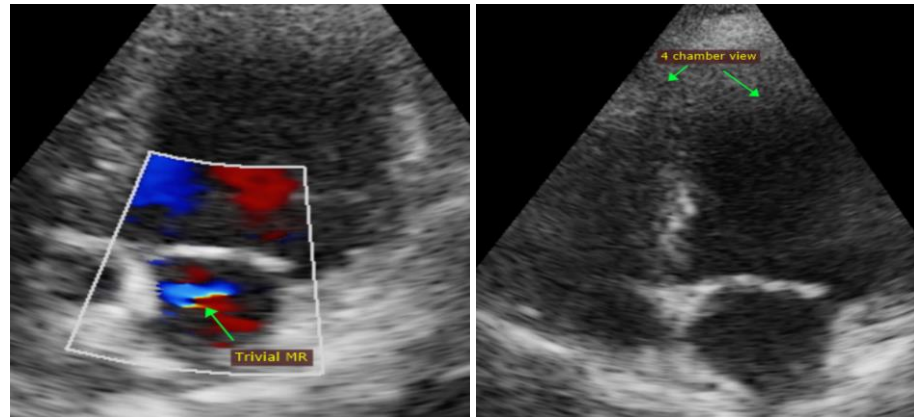
BREED

Pitbull Mix

A recheck echocardiogram is recommended 1 year, sooner if a murmur or signs of cardiac compromise be noted in the future.

SEX

Female Spayed

IMAGES**AGE**

9 years

WEIGHT

57lbs

The information and recommendations provided are based on the images presented by the referring veterinarian. No evaluation can be communicated regarding pathology that was not visible in the image/video clips provided.

INTERPRETED BY

Maggie Machen Lamy,
DVM, DACVIM
(Cardiology)

Thank you for this referral. If the clinical or image interpretation does not parallel your findings or if I can be of any further assistance, please contact me.

IMAGING PERFORMED BY

Amy Mayhew, LVT

Maggie Machen Lamy, DVM
Diplomate of the American College of Veterinary Internal Medicine (Cardiology)
 info@sonopath.com

HOSPITAL NAME

SVS Imaging MI

REFERRING VET

Family Pet Practice

INVOICE

23601

DATE

4/12/22